



6th Advanced Course on Knee Surgery

January 31st – February 5th, 2016 Val d'Isère - France

Techniques of reconstruction: How I do MPFL using Quadriceps

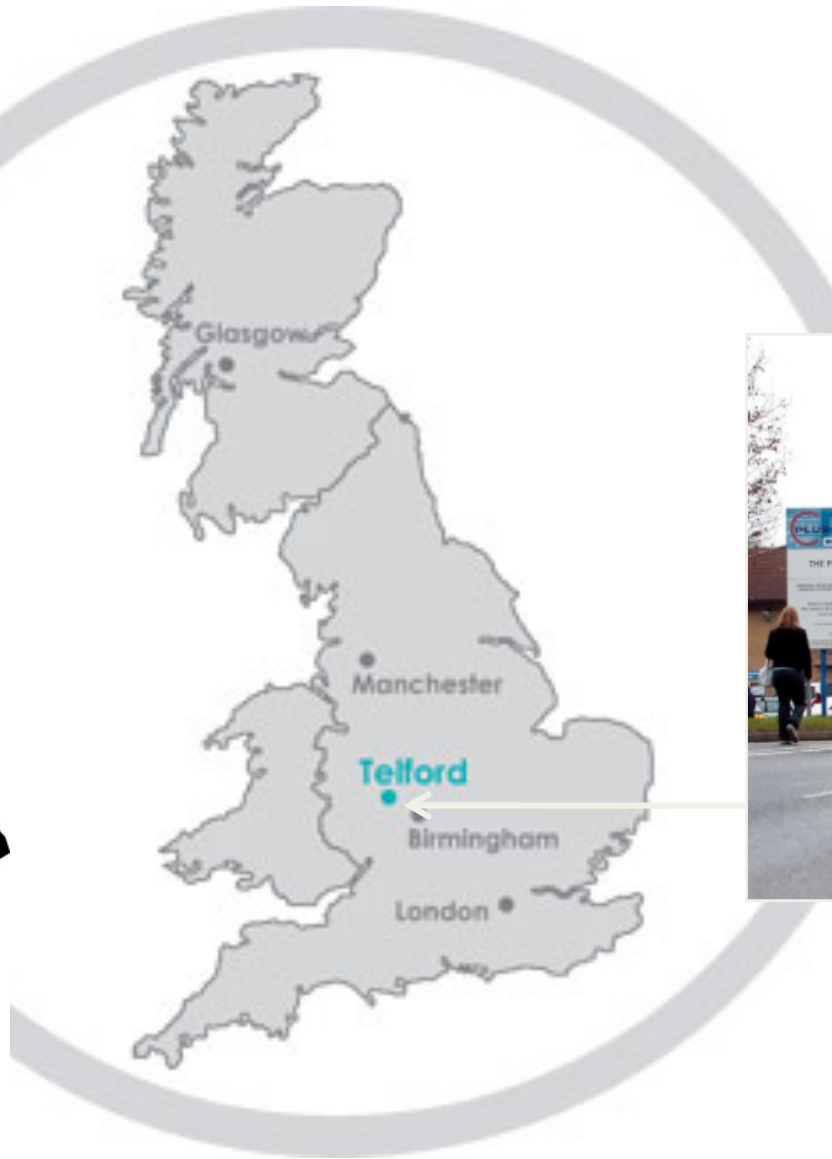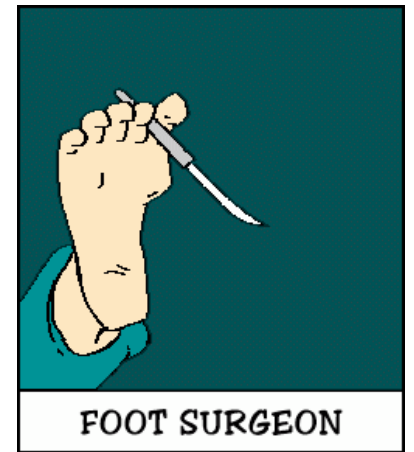Mike Carmont



Val d'Isère



Where is Telford?



Probably better known for...



Technique

Technical Note

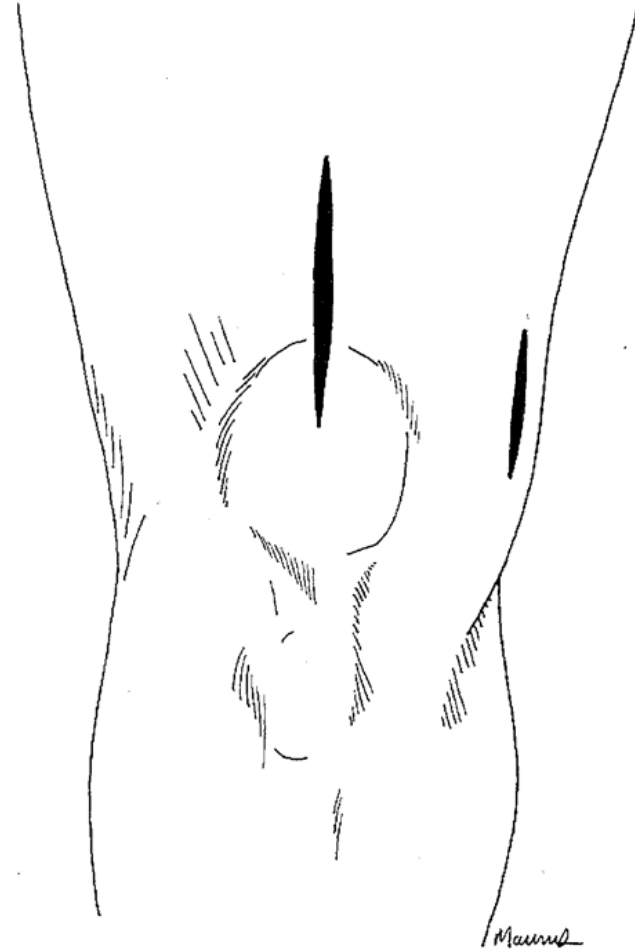
A Simple Technique for Reconstruction of the Medial Patellofemoral Ligament Using a Quadriceps Tendon Graft

Robert N. Steensen, M.D., Ryan M. Dopirak, M.D., and Peter B. Maurus, M.D.

Steenson Arthroscopy 2005;21(3):365-370

Set up

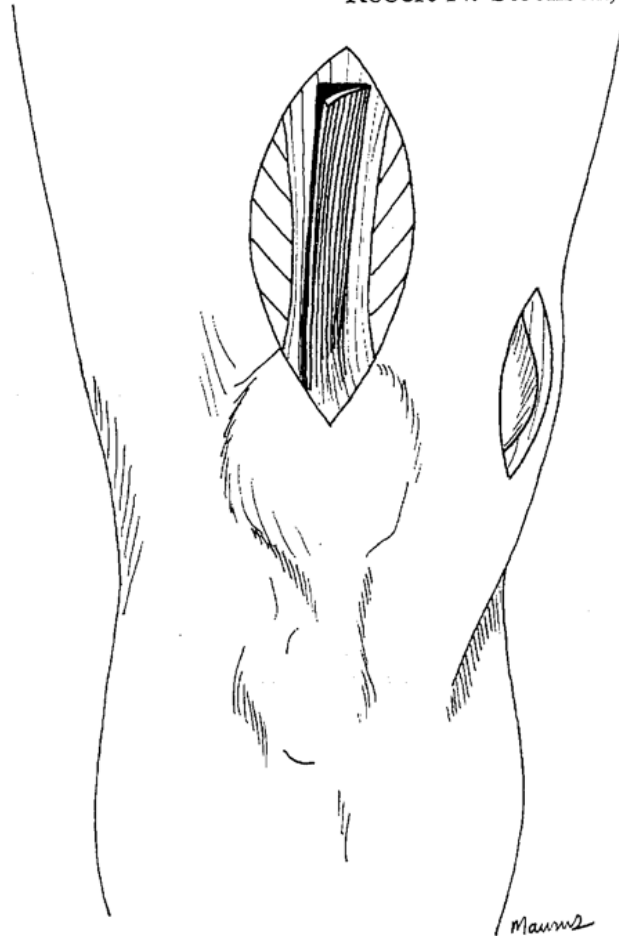
- Supine
- Knee 90° flexion
- High tourniquet
- Arthroscopy SL portal



Technical Note

A Simple Technique for Reconstruction of the Medial
Patellofemoral Ligament Using a Quadriceps Tendon Graft

Robert N. Steensen, M.D., Ryan M. Dopirak, M.D., and Peter B. Maurus, M.D.



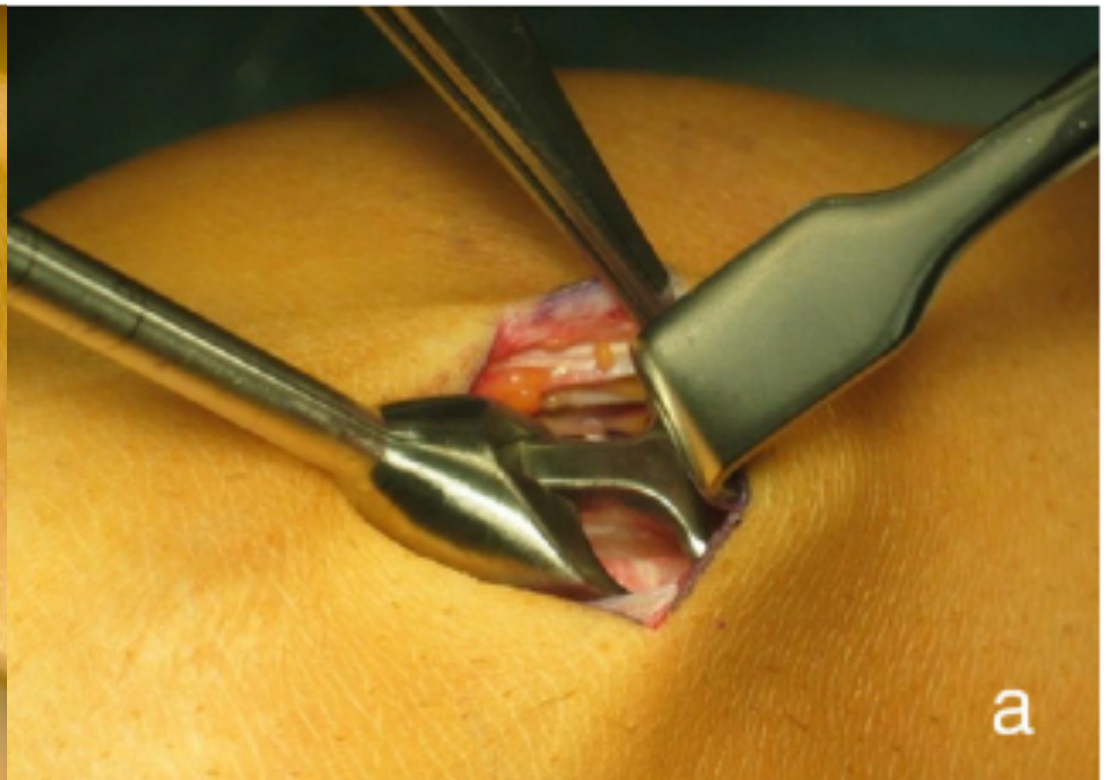
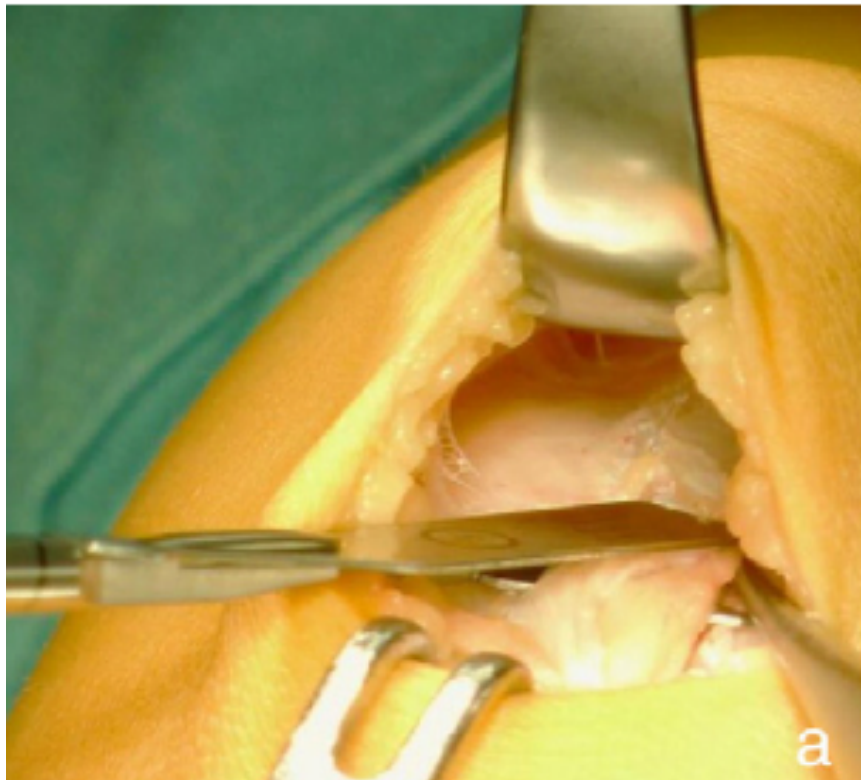
- Trilaminar structure
- Anterior Lamina
- Tendon Rectus Femoris

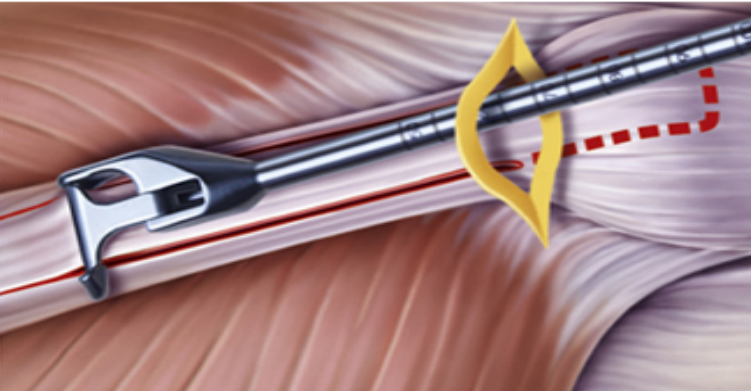
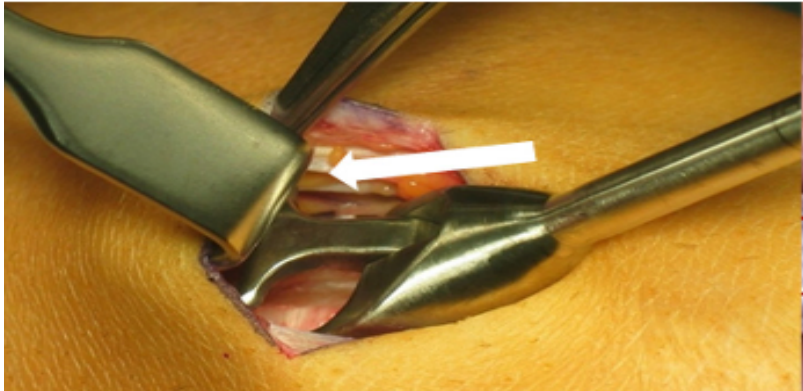

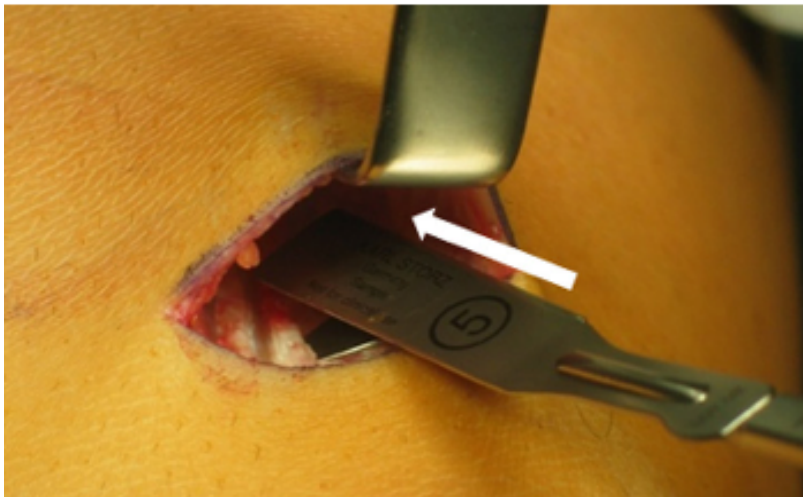
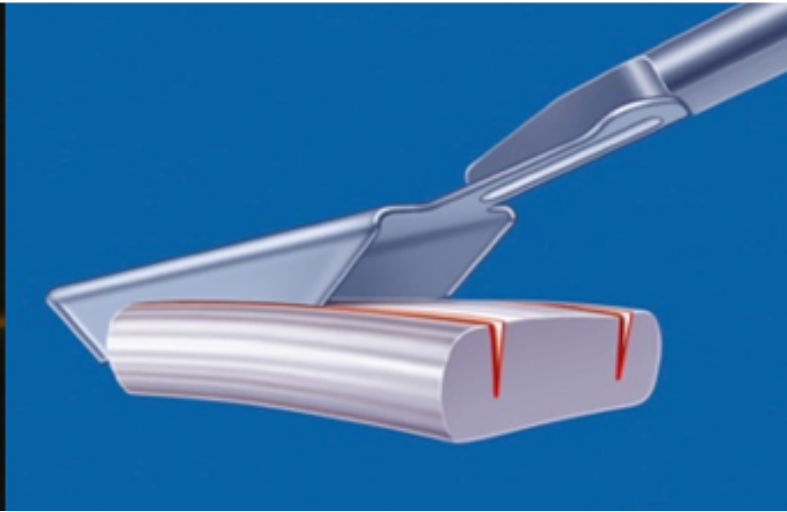
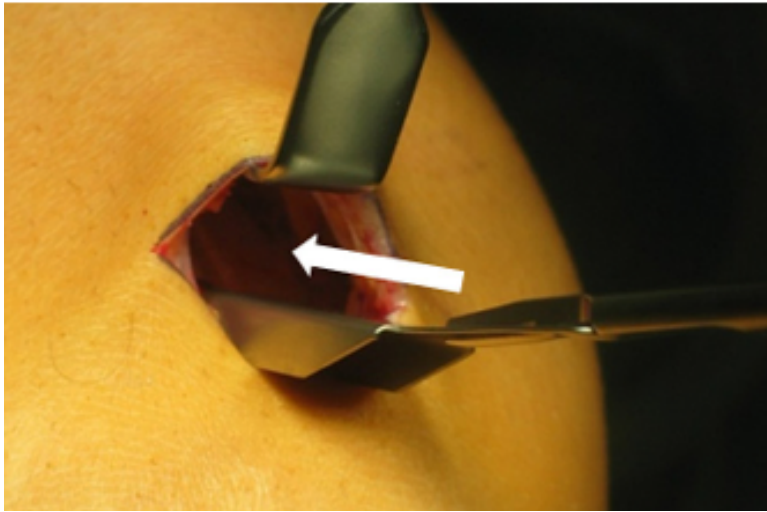
MPFL reconstruction using a quadriceps tendon graft[☆]

Part 2: Operative technique and short term clinical results



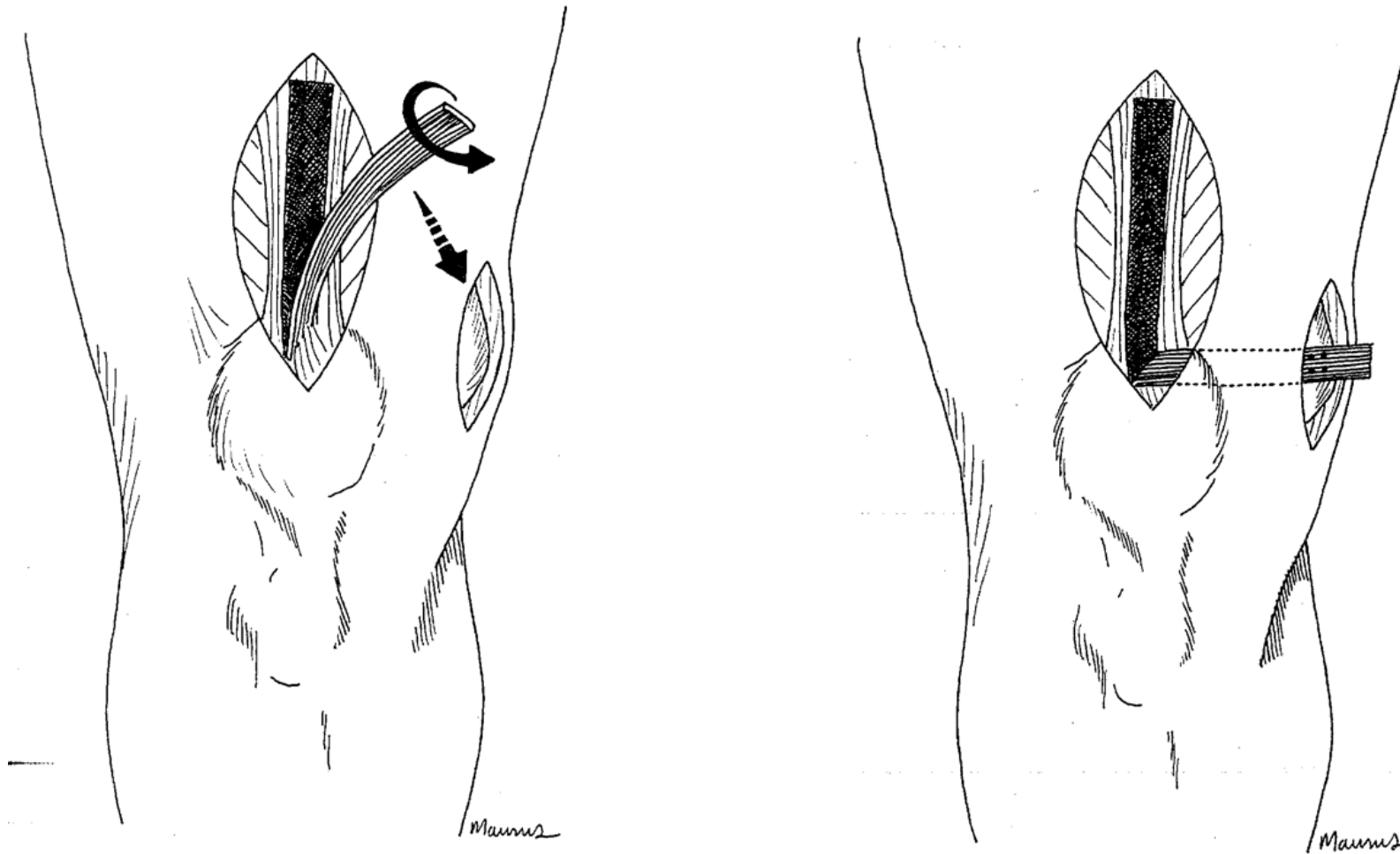
Christian Fink^a, Matjaz Veselko^c, Mirco Herbort^b, Christian Hoser^{a,*}





Fink
Arthro Tech
2014

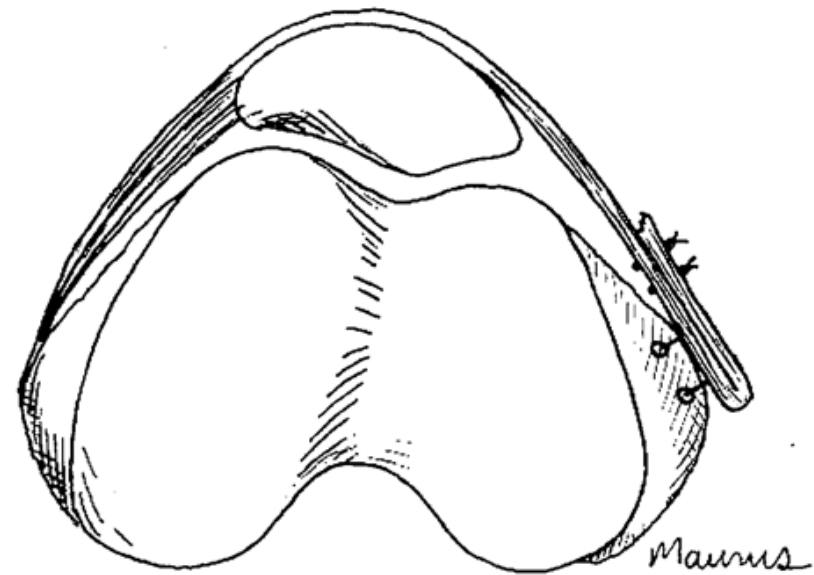
Open Technique



Adequate length, 90°, 45° angle sutured, passed 2nd layer knee, extracapsularly between superficial and deep ligament [Warren 1979 JBJS]

Fixation

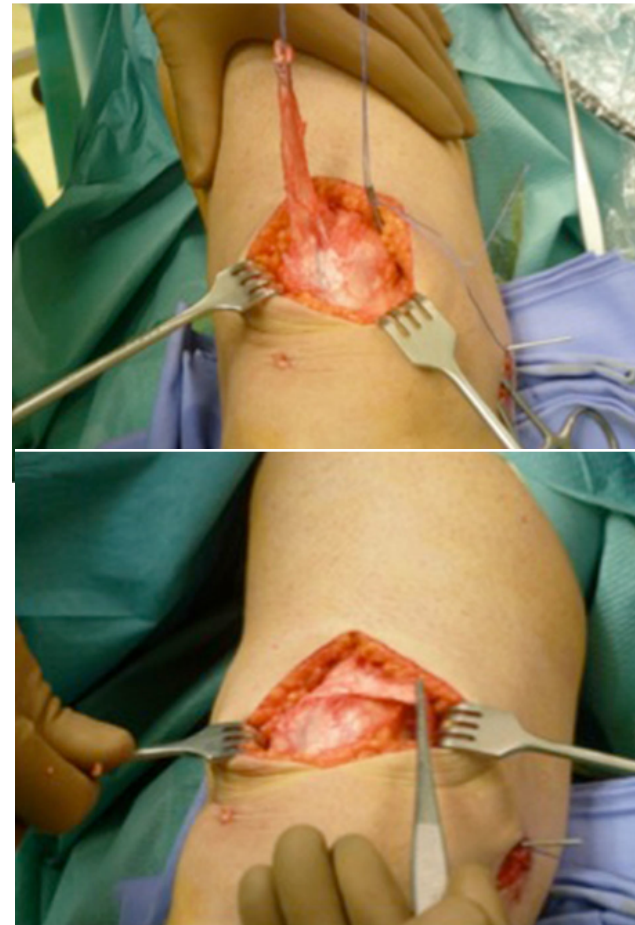
- Original technique
- Suture fixation
- Whip stitch
- Interference screw fixation at insertion of MPFL
- Fluoroscopy



Isolated reconstruction of the medial patellofemoral ligament with autologous quadriceps tendon

Giovanni Vavalle^{1,2} · Michele Capozzi¹

- 16 patient
- Open harvest, suture anchors
- 38months follow up
- Kujala 35.6 > 88.8
- Lysholm 43.3 > 89.3
- Partially satisfied outcomes grade 3 & 4 patella

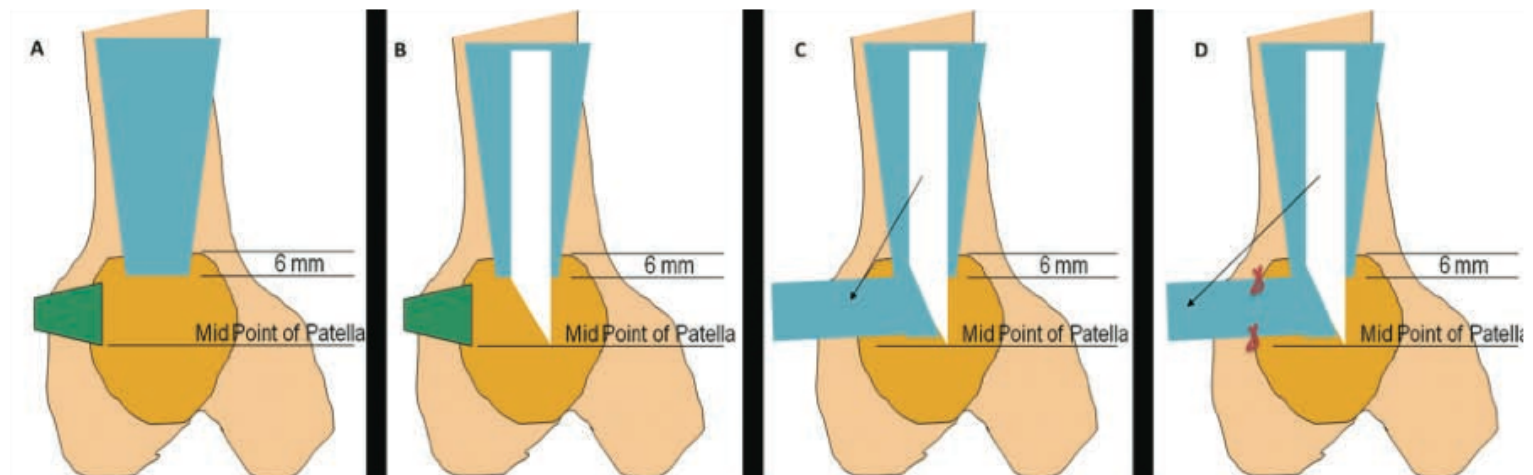
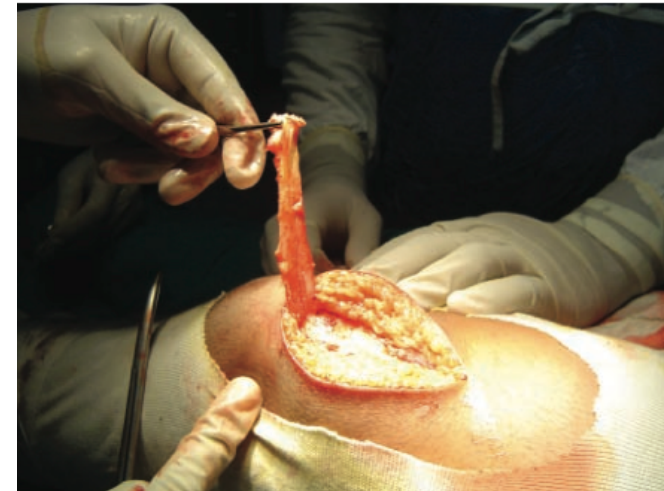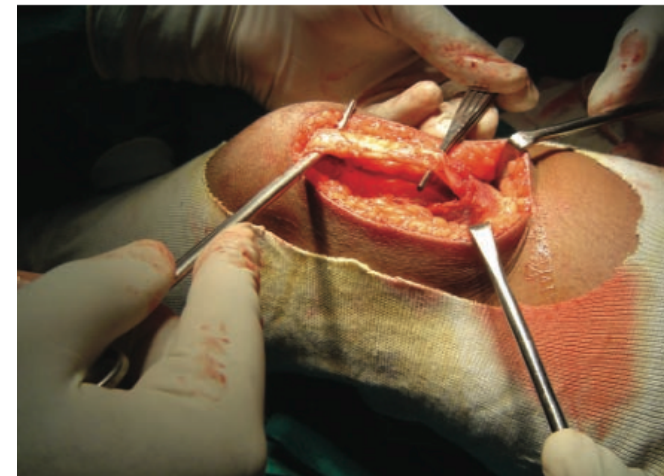


Medial Patellofemoral Ligament Reconstruction

The Superficial Quad Technique

Deepak Goyal,^{*†} MB, MS(Ortho), DNB(Ortho), MNAMS

- 32 patients (22F)
- Ave 38 months
- Kujala 49.3 > 91.3
- 30° flexion, manual tightening with titanium screw



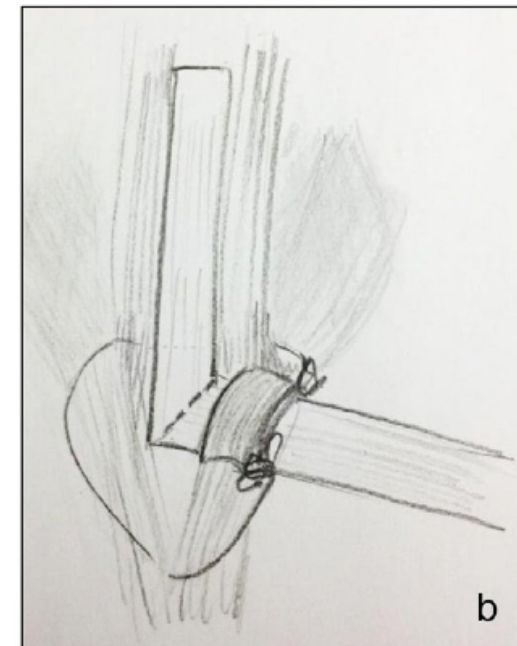
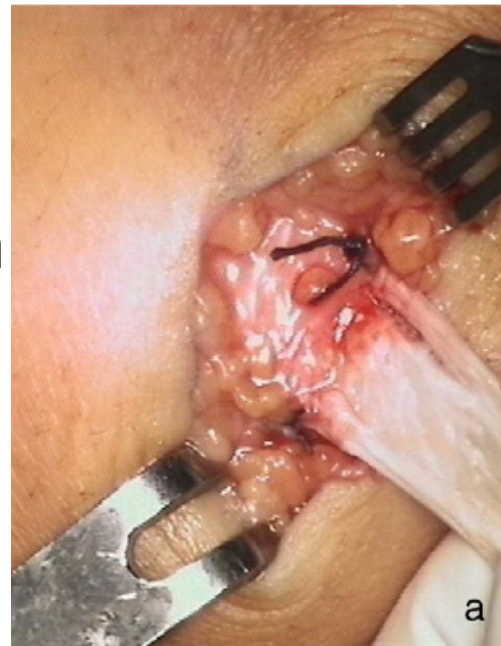MPFL reconstruction using a quadriceps tendon graft[☆]

Part 2: Operative technique and short term clinical results



Christian Fink^a, Matjaz Veselko^c, Mirco Herbort^b, Christian Hoser^{a,*}

- 17 patients (10F)
- 20° knee flexion with lateral border patella flush with lateral trochlea
- Bio screw
- At 12 months
 - Kujala 89.2
 - Lysholm 88.1
 - Tegner 5



Summary

- Quadriceps
- Local tendon
- Minimally invasive technique
- Small risk of detachment
- No donor sacrifice
- Low risk patella fracture
- No prominent endobutton